

Recognition and Management of Vulvar Dermatologic Conditions: Lichen Sclerosus, Lichen Planus, and Lichen Simplex Chronicus

CEU

Katrina Alef Thorstensen, CNM, MSN, Debra L. Birenbaum, MD

Lichen sclerosus, lichen planus, and lichen simplex chronicus are dermatologic conditions that can affect the vulva. Symptoms include vulvar itching, irritation, burning, and pain, which may be chronic or recurrent and can lead to significant physical discomfort and emotional distress that can affect mood and sexual relationships. With symptoms similar to common vaginal infections, women often seek care from gynecological providers and may be treated for vaginal infections without relief. Recognition and treatment of these vulvar conditions is important for symptom relief, sexual function, prevention of progressive vulvar scarring, and to provide surveillance for associated vulvar cancer. This article reviews these conditions including signs and symptoms, the process of evaluation, treatment, and follow-up, with attention to education and guidelines for vulvar care and hygiene.

J Midwifery Womens Health 2012;57:260–275 © 2012 by the American College of Nurse-Midwives.

Keywords: dyspareunia, erosive, lichen planus, lichen sclerosus, lichen simplex chronicus, vulvar dermatitis, vulvar dermatosis, vulvar itching, vulvitis



A related patient education handout can be found at the end of this issue and at www.sharewithwomen.org

INTRODUCTION

A woman presents with vulvar itching she has had on and off for weeks. She has seen other providers and has been treated for yeast infection and bacterial vaginosis, but the symptoms keep coming back, and she is frustrated. She wants to know why she keeps getting the symptoms and what will make them better.

This situation will be familiar to clinicians who provide gynecologic care. Recurrent vaginitis, while not uncommon, is not the only cause of such symptoms. Lichen sclerosus, lichen planus, and lichen simplex chronicus are dermatologic conditions that can affect the vulva and cause chronic or recurrent vulvar irritation, itching, burning, and pain. Women with these conditions may experience considerable distress. There can be continual discomfort in an area of the body that for many women is private, sometimes embarrassing, and about which misinformation and underlying fears are common.^{1–3} Women also may feel frustration at being unable to find an accurate diagnosis and effective treatment for their symptoms.⁴ All of this can have a profound effect on mood, sexual function, and intimate relationships, as expressed by women seen in a referral vulvar practice: “I’m scared I won’t find out what’s wrong, and I’ll never get better”; “I hardly ever have sex with my boyfriend/husband”; and “I’m miserable—work and love life are horrible.”

Address correspondence to Katrina Alef Thorstensen, CNM, MSN, Dartmouth-Hitchcock Medical Center, Department of Obstetrics and Gynecology, 1 Medical Center Drive, Lebanon, NH, 03756. E-mail: katrina.thorstensen@hitchcock.org

Certified-nurse midwives (CNMs), certified midwives (CMs), and other clinicians who provide primary gynecologic care are likely to see women with lichen sclerosus and lichen simplex chronicus, and, while lichen planus is less common, early recognition is important. This article presents information so that midwives and other clinicians can provide or help these women find effective care.

EVALUATION FOR ALL VULVAR CONDITIONS

Providing care to women with vulvar conditions is often challenging and time consuming. These conditions can be difficult to evaluate, do not always respond to treatment, and may improve gradually. Often more than one visit is needed, and women should be told this in the beginning to avoid unrealistic expectations.

History

Women with vulvovaginal conditions often have an extensive history of symptoms, diagnoses, and treatments. A detailed history of the symptoms should be obtained, including time of onset, chronologic course, specific location, and exacerbating and alleviating factors. The most important question may be asking the woman what she is most concerned about. Women have often seen other providers and used several prescription and over-the-counter medications and products; it is useful to find out what was used and if the treatment helped. Obtain past records if possible, particularly test results and biopsy reports.

A full medical, surgical, gynecologic, obstetric, and dermatologic history should be reviewed, including medications, allergies, and systems review. Important aspects of the history and systems review for vulvar conditions are detailed in Table 1. Vulvar and menstrual hygiene practices, with particular attention to potential vulvar irritants, and a



Table 1. Important Aspects of History/Systems Review in Evaluating Women with Vulvar Conditions**Chief Concern and Associated Symptoms**

Quality	Itching, irritation, pain, burning, stinging, raw, tearing
Duration	Weeks, months, years
Timing	Onset, chronology, symptoms since onset
Pattern of symptoms	Worse, better, or same since onset Spontaneous or provoked Same throughout day or worse at night
Relation to menses	Before, after, worse, or better
Previous treatments	Over-the-counter, prescribed, other; results
Vaginal discharge	Color, quality, odor, association with itching or discomfort
Other symptoms	Fissuring, bleeding, pain with bowel movements
Factors that worsen symptoms	Friction, heat, moisture Physical activities Sexual activity/intercourse Urine, stool Clothing, undergarments Topical medications or products
Factors that alleviate or improve symptoms	Topical medication or products Avoiding certain physical activities Avoiding sexual activity/intercourse
Impact on daily life	Bathing, exercise, work, sleep, mood, sex, relationships

Hygiene

Frequency	
Products used	Soaps, bar or liquid, shower gels, brands
Cleansing method	Washcloth, loofah, puff
Hygiene products	Douches, sprays, deodorants, wipes
Menstrual products	Tampons, pads, panty liners (daily or menses), scented/unscented, brands
Urine, stool	Incontinence products, perianal hygiene practices
Other	Shaving, use of lotions, creams, powders, perfumes

Sexual history and relation to symptoms

History	Currently, not at present, never One partner, multiple partners, new partner(s) Sex of partner(s)
Symptoms	During, before, after sexual activity/intercourse
Preference	Does she want to be able to have sexual activity/intercourse?
Function	Is she able to have sexual activity/intercourse if desired?
Impact	Impact of symptoms on sexual function and relationships

Gynecological history

Menses	Timing of symptoms with menses, effect on symptoms
Contraceptive method	Type, effect on symptoms
Vaginitis, vulvar disease	Yeast, bacterial vaginosis, trichomoniasis, inflammatory vaginitis, vulvodynia, other
Sexually transmitted infection	Herpes simplex virus, genital warts (human papillomavirus), chlamydia, gonorrhea, HIV, other
Menopause	Effect on symptoms, atrophic vaginitis, use of hormone therapy and/or vaginal estrogen
Other	Abnormal Papanicolaou test results, pelvic pain, pelvic surgery

Continued.

Table 1. Important Aspects of History/Systems Review in Evaluating Women with Vulvar Conditions

Obstetric history	
Pregnancies	Relation to symptoms, complications
Births	Relation to symptoms, type of birth, episiotomy or lacerations, complications
Dermatologic history	
Skin	Eczema, psoriasis, atopy, allergies, sensitivities, contact dermatitis, vitiligo, skin cancer
Mucus membranes	Mouth, gum, or scalp problems; oral lichen planus
Medical history	
Autoimmune, endocrine, rheumatologic	Thyroid disease, diabetes, arthritis, other autoimmune
Gastrointestinal	Irritable bowel syndrome, Crohn disease, ulcerative colitis, other inflammatory bowel disease, anal fissures
Neurological	Back pain/problems, chronic pain
Psychiatric	Depression, anxiety, insomnia, other
Other	Asthma
Medications	Systemic, topical, prescription, nonprescription, compounded, naturopathic, herbs, supplements
Allergies	Medications, environmental, seasonal, food
Family history	Dermatologic (eczema, atopy), asthma, thyroid, other autoimmune
Review of systems	
Constitutional	General well-being, sleep, weight gain or loss
Skin	Itching, irritation, burning, erythema, scaling, ulceration or other skin symptoms on other areas of body
Mucus membranes	Mouth or gum sores, other
Atopy	Environmental/seasonal allergies, sensitivities, rhinitis
Gastrointestinal	Diarrhea, constipation, pain and/or bleeding with bowel movement, fecal incontinence, hemorrhoids, anal fissures, abdominal pain
Urinary	Incontinence, dysuria, urgency, frequency, hesitancy
Psychiatric	Depression, anxiety, insomnia

Sources: Schlosser and Mirowski⁵; Margesson.¹¹

sexual history, including the woman's specific concerns, are also important, as detailed in Table 1.

A questionnaire filled out prior to the appointment can be helpful in obtaining detailed information. A sample questionnaire used by a referral vulvar clinic may be helpful as a reference (see Supporting Information: Questionnaire S1).

Examination

Lichen sclerosus, lichen planus, and lichen simplex chronicus can cause changes in the color, texture, and architecture of the vulvar anatomy. To recognize these sometimes subtle changes, the clinician must be familiar with normal vulvar anatomy and variations, which are affected by age, ethnicity, hormones, and individual factors.⁵ It is important to take time to examine the entire vulva, from above the clitoris to below the anus (see Figure 1). Make sure all parts are present, including the labia minora and clitoris. Changes in anatomy easily can be missed without a deliberate examination. The clitoral hood should be mobile and easily retracted to visualize the clitoral glans. Examine the labia majora, labia minora, inter-

labial sulcus, the perineum, and perianal folds for color and texture and for fissuring, excoriation, erosions, ulcerations, and lesions. A speculum examination (if tolerated by the patient) should be performed to examine the vaginal mucosa and cervix for erythema, erosions, ulcerations, synechia, and discharge and to obtain cultures and a wet preparation sample when indicated. A bimanual or digital vaginal examination should be done if tolerated to evaluate the length of the vaginal canal.

Vaginal discharge should be evaluated. This includes checking pH and microscopic assessment of squamous cells, the presence or absence of lactobacilli, white blood cells, and bacteria, which provides information regarding infection, inflammation, and hormonal status.⁶ A potassium hydroxide slide may be done to examine for yeast, but a yeast culture is necessary, at least at the initial evaluation, because yeast is seen on wet preparations only 20% to 50% of the time, and non-*albicans* strains of yeast such as *Candida glabrata* are difficult to identify without a phase contrast microscope.⁶⁻⁸ The vaginal walls and discharge should be cultured for yeast, and any areas of vulvar erythema, fissuring, or excoriation should

Table 2. Products and Agents that May Cause or Worsen Vulvar Irritation

Type	Product or Agent	Recommendations
Hygiene and bath	Soaps, particularly antibacterial and liquid	Use unscented bar soap (eg, Dove, Cetaphil, Basis, Vanicream).
	Wash cloths, loofahs, bath and shower puffs	Use hands only to cleanse vulva.
	Baby wipes, personal wipes	Avoid all.
	Bubble baths, bath oils, shower gels, shaving cream or foam	Avoid all.
	Men's shaving cream, aftershave, cologne	Avoid all.
Toilet	Scented or colored toilet paper, wipes	Use white unscented toilet paper. For perianal hygiene: water, mineral oil, or unscented liquid soap (such as listed above).
Laundry	Detergent additives, bleach, fabric softeners, dryer sheets	Use fragrance-free detergent, avoid additives.
Clothing	Tight clothing or undergarments, pantyhose, girdles or undergarments with spandex, thongs	Avoid constrictive undergarments/clothing; wear cotton underwear.
	Wet or sweaty exercise clothing	Change clothing after exercise.
Menstrual care products	Panty liners, pads, particularly daily use and brands with scents or additives to retain moisture (eg, Always panty liners ^a)	Use unscented products for menses only or as infrequently as possible.
Feminine hygiene products	Douches, sprays, powders, perfumes	Avoid all.
Body fluids	Urine, feces, menstrual blood	Address urinary incontinence, perianal hygiene.
Over-the-counter antifungal medications	Miconazole (Monistat) and all intravaginal azoles	Treat vulvovaginal candidiasis due to <i>Candida albicans</i> with oral fluconazole (Diflucan) if possible.
Over-the-counter anti-itch and other vulvar products	Products containing benzocaine (eg, Vagisil, Vagicaine, and Lanacane)	Avoid all.
Prescription medications	Including terconazole (Terazol), trichloroacetic acid, podophyllin, imiquimod (Aldara), 5-fluorouracil	Consider irritant potential of these.
Spermicidal agents		Some may be irritating.
Lubricants	Personal lubricants that "heat on contact" or that contain chlorhexidine	Use a fragrance-free lubricant (eg, KY jelly, Astroglide, Slippery Stuff).

Sources: Schlosser and Mirowski⁵; Margesson¹¹; Eason and Feldman.¹²

be swabbed as well. Make sure the laboratory can perform a specific yeast culture that identifies *Candida* species—a routine genital culture does not provide this necessary information and is inadequate. A yeast infection may or may not be the primary cause of the woman's symptoms but should be treated if present.

It is important to keep in mind that women with vulvar conditions may have more than 1 condition, and reevaluation is often necessary.

Biopsy

A biopsy is necessary for the diagnosis of many vulvar dermatologic conditions, including lichen sclerosus and lichen planus. While history and examination may be suggestive, the clinical appearance of these conditions is not always diagnostic.⁴ In addition, lichen sclerosus and lichen planus are life-

long conditions, requiring long-term treatment and follow-up, and a biopsy prior to obligating women to this is important. A biopsy also is indicated for any lesions, nodules, erosions, or ulcerations suspicious for vulvar intraepithelial neoplasia (VIN, which is precancer) or vulvar cancer.⁹ A biopsy should not be done if the skin appears normal. Use of a topical corticosteroid prior to a biopsy can interfere with results; women should refrain from using these 2 to 3 weeks before a biopsy is performed.

The site for the biopsy should be the area of the vulva that appears most characteristic of the condition; a novice may need assistance from a more experienced clinician to determine this. Avoid the clitoris if possible. Only 1 biopsy is needed unless there is a concern for VIN or cancer. Local anesthesia should be provided with topical lidocaine prilocaine cream (EMLA 2.5%) applied for 10 to 15 minutes,

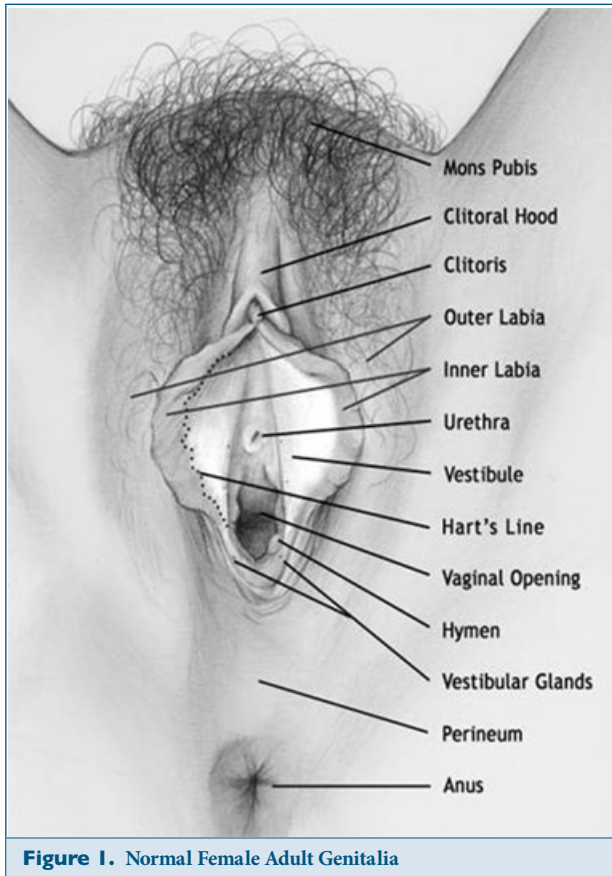


Figure 1. Normal Female Adult Genitalia

Reprinted with permission from Dawn Danby.

followed by instillation of 1% lidocaine with 1:100,000 epinephrine. A punch biopsy is not difficult to learn; sources of instruction include gynecologic or dermatologic colleagues and continuing education programs. After a biopsy, women may experience discomfort for 1 to 2 days and may use acetaminophen, ibuprofen, and/or ice. Petroleum jelly (Vaseline) can be applied topically, but other topical medications should be avoided until the site has healed.

Specialized dermatopathologists with experience reading skin biopsies are very helpful when interpreting biopsies. Provide as much information as possible about the clinical history and examination findings on the pathology requisition to assist the pathologist in making an accurate diagnosis. A negative biopsy does not necessarily mean absence of disease. If the biopsy is negative or inconclusive, and the woman has persistent symptoms or clinical signs of vulvar disease, a referral to a vulvar gynecology or dermatology specialist is recommended.

MANAGEMENT GUIDELINES FOR ALL VULVAR CONDITIONS

Avoidance of Irritants and Comfort Measures

Women with recurrent or chronic vulvovaginal conditions often have symptoms not only from the condition itself but also from resulting scratching and rubbing; cleansing routines and products; exposure to urine, menses, and stool; and medications and products used to alleviate symptoms.³ The vulva is more permeable than exposed skin and is particularly vulner-

able to irritants.¹⁰ Women who are estrogen deficient (postpartum, menopause, and medication induced) may be even more vulnerable.¹¹ All of these can cause a breakdown in the natural barrier function of the vulvar skin, making it susceptible to secondary infection.

The first step in treating all vulvar conditions is to eliminate all sources of irritation.¹¹ A list of vulvar irritants shown in Table 2 includes products that women commonly use. Women often are unaware of the irritation that can be caused by these products, which are socially accepted and promoted in the media.¹² In one study of 530 women attending a specialty vulvar clinic, more than 60% described using potentially unfavorable vulvar products.¹³ Many over-the-counter products for vulvovaginal symptoms contain sensitizing ingredients, and over-the-counter antifungal medications can be very irritating, especially the 1-day products.³ It may be helpful to tell women that while these products may not have caused their symptoms, eliminating all possible irritants is the first step in their care.

Women should be instructed to avoid scratching and rubbing. Comfort measures include cool gel packs, sitz baths, refrigerated petroleum jelly, and cold yogurt on a pad. Petroleum jelly is nonirritating and very soothing; it can be used anytime an ointment is desired and liberal use is encouraged especially in postmenopausal women. Applying after showering, bathing, or soaks can soothe irritated vulvar skin. Giving women written information on vulvar care and hygiene and avoidance of irritants is helpful (see the Share with Women patient education handout in this issue).

Use of Corticosteroid Ointments

Topical corticosteroid medications frequently are used for vulvar dermatologic conditions to treat symptoms, decrease inflammation, and prevent disease progression and scarring. Ointments, which do not contain alcohol or preservatives, are less irritating than creams and are recommended for the sensitive vulvar tissue. The modified mucous membranes of the vulva are relatively steroid resistant, so potent corticosteroids often are required and are safe when used as instructed.³ A list of all topical steroids can be found in many dermatology references.¹⁴ Table 3 lists the corticosteroid ointments recommended for the vulvar conditions in this article (treatment regimens are detailed in the sections on specific conditions).

It is very important to instruct the woman exactly how to use the prescribed steroid ointment. Especially with superpotent topical steroid ointments, women must use a scant amount to avoid side effects that can occur from overuse, such as tissue thinning, striae, and rebound steroid dermatitis. Instruct the woman to use the amount a toothpick picks up, usually much less than expected, and demonstrate this as shown in Figure 2. Show her exactly where to apply it using a mirror during the examination if she is comfortable with this, or use a diagram of the vulva (Figure 1). Prescribe only a 15-g tube of ointment without a refill to prevent overuse.

While it is important to warn against overuse, it is often equally necessary to encourage women to continue to use their topical medications as prescribed. They may be suspicious of steroids in general, and written information provided with the medication warns against long-term use. The

Table 3. Suggested Topical Corticosteroid Ointments for Vulvar Conditions^a

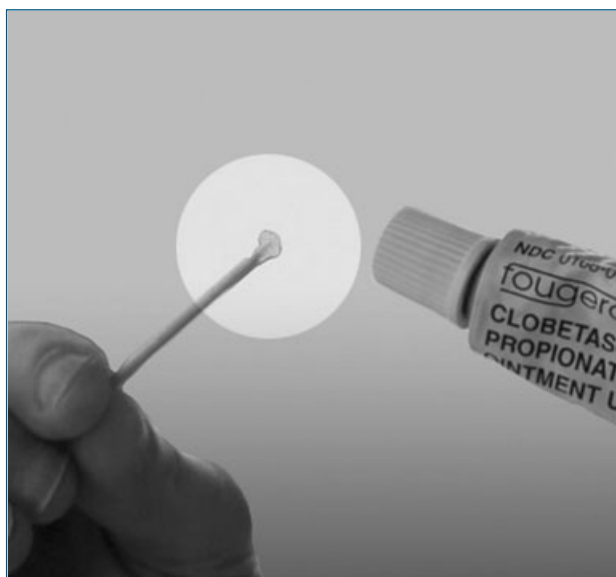Classification	Generic Name	US Brand Name
Class I: Super high potency	Clobetasol propionate 0.05% ointment	Temovate
	Halobetasol propionate 0.05% ointment	Ultravarate
Class II: High potency	Triamcinolone acetonide 0.5% ointment	Kenalog Aristocort
Class III: Midpotency	Mometasone furoate 0.1% ointment	Elocon
Class V: Low to midpotency	Prednicarbate 0.05% ointment	Dermatop
Class VII: Very low potency	Hydrocortisone 2.5% ointment	Hytone

^aOintments, rather than creams, should be used for vulvar conditions. Use generics whenever possible. Source: Ferenc and Last.¹⁴

importance of following the prescribed treatment to prevent disease recurrence and progression and the safety of the medication when used as prescribed must be reinforced over many visits.

Use of Sedating Medications

Women with vulvar itching may scratch or rub and are not always aware of it, often at night. This can worsen the skin condition. For significant nighttime itching, consider use of a nighttime sedating agent. Nonprescription oral diphenhydramine (Benadryl) can be used. Hydroxyzine is a prescription antihistamine that has sedative and antihistamine effects; the typical dose is 10 to 30 mg orally about 2 hours before bedtime; instruct the woman to start with 10 mg and increase up to 30 mg if needed. If these are not effective, oral doxepin (10 mg about 2 hours before bedtime) may be tried for severe cases; it is much more potent than hydroxyzine.

**Figure 2. Demonstrating the Amount of Steroid Ointment to Use**

Reprinted with permission from Debra L. Birenbaum, MD.

Sexual Function

Recurrent or chronic vulvar symptoms may affect women's sexual function and relationships, mood, and self-esteem.¹⁵ Pain or discomfort with sex often leads to decreased interest and frequency, compounding the problem.¹⁶ Sexual function and relationships are personal issues that some women may find difficult to talk about. It is important to inquire in a way that allows women to express concerns as comfortably as possible and to provide support based on individual needs. For some women, sexual function is not important; for others it is a significant concern. For premenopausal women, contraceptive choices and pregnancy may need to be considered. Postmenopausal women with vulvar conditions often need vaginal estrogen (if not contraindicated) in order to have comfortable intercourse. A vaginal dilator may be needed by some women to maintain vaginal patency. Offering resources and/or a referral to a sex therapist may also be helpful in some cases.

Education

Education is an essential aspect of care for women with all vulvar conditions. These conditions are not well known, so it is important to discuss them and provide accurate written information that women can refer to after the visit. It is very important to let women know that they do not have a sexually transmitted infection or cancer; both are often hidden concerns.¹⁵ Information about vulvar care and hygiene should be provided and reinforced at every visit. Providing recommendations for reliable Internet resources is also helpful; some are listed in Appendix 1.

Follow-up and Referral

A follow-up visit usually is scheduled 1 to 3 months after the initial evaluation. Subsequent visits are based on the woman's condition, response to treatment, and individual needs. Women should also be seen as needed for persistent or recurrent symptoms. Women with vulvar conditions do not always improve after initial diagnosis and treatment, and reevaluation may be necessary.

Referral to a vulvar specialist (gynecologist or dermatologist) is recommended when the evaluation, testing, and/or biopsy are inconclusive; for women who do not respond to

treatment; for women with persistent, recurrent, or advanced disease; or when the needs of the woman are beyond what the clinician is able to provide. The International Society for the Study of Vulvovaginal Disease provides referrals to vulvar specialists through its Web site (Appendix 1). If this is not possible, collaborative management with, or referral to, a gynecologist or dermatologist who has experience with vulvar disease is suggested.

LICHEN SCLEROSUS

Lichen sclerosis (see Box 1) is a benign, inflammatory, immune-mediated skin disease that usually affects the genital area.¹⁷ Often unrecognized and underdiagnosed, its prevalence has been difficult to determine but is estimated at 1 in 300 to 1 in 1000 women.^{18,19} One study showed that lichen sclerosis affected 1 in 30 elderly women in a nursing home.²⁰ It is 10 times more common in women than in men, most common in white and Hispanic women, and rare in African Americans. It can affect women of all ages but is most common in perimenopausal and postmenopausal women. Lichen sclerosis also is seen in prepubertal girls in about 15% of cases; their evaluation and care is usually provided by pediatricians and vulvar specialists²¹ and is beyond the scope of this article.

The etiology of lichen sclerosis is not clearly known and probably is multifactorial; studies suggest that both genetic and autoimmune factors are involved. One study showed that

12% of more than 1000 patients with lichen sclerosis had a positive family history.²² An infective trigger has been suggested, based on an association with the bacteria *Borrelia burgdorferi* in Europe, but not in the United States^{23,24}; this may be one of many environmental triggers for lichen sclerosis in genetically susceptible individuals.²⁵ Studies show an increased incidence of basement membrane zone antigens and autoantibodies to extracellular matrix proteins in patients with lichen sclerosis.^{26,27} An association with human leukocytic class II antigen that may be involved in susceptibility to and protection from lichen sclerosis also has been reported.²⁸

Autoimmune diseases are common among women with lichen sclerosis. Up to 20% of women with lichen sclerosis have other autoimmune diseases such as thyroid disorder, vitiligo, alopecia areata, lupus, and pernicious anemia; up to 44% of these women have autoantibodies, especially thyroid autoantibodies.^{29,30} In a study from northern New England, 28% of women with biopsy-proven lichen sclerosis had a history of thyroid dysfunction, mostly hypothyroidism, a 5-fold to 30-fold increase over the incidence in the general population, although geographic variation may be a factor.³¹ Low estrogen levels also have been questioned as a factor in the development of lichen sclerosis, as it is most often seen in postmenopausal women and prepubertal girls.³²

Symptoms of Lichen Sclerosis

Vulvar itching is the most common symptom of lichen sclerosis, ranging from mild and intermittent to intense, constant, and intractable.^{16,25} Women report vulvar fissures (small cracks or linear skin tears) that occur spontaneously, with intercourse, and from scratching.²⁵ There may be dysuria or pain with defecation, the latter seen more often in children.³³ Women with perianal lichen sclerosis may have perianal itching, burning, and anal fissuring that causes rectal bleeding. Pain with intercourse is very common, especially in postmenopausal women. Postmenopausal vulvar atrophy, progressive scarring, and loss of elasticity can cause the perineum to split and make sexual activity difficult or impossible.^{1,15,34} Dyspareunia may be the only presenting symptom, and it may have been attributed to postmenopausal atrophy or yeast vaginitis.

It is important to remember that lichen sclerosis can also be entirely asymptomatic or so mild that the woman does not notice or report symptoms. It may be discovered during a routine gynecological examination in a woman with no symptoms at all.¹⁶

Examination

Lichen sclerosis causes characteristic changes in color and often vulvar anatomy. Examples of the appearance of lichen sclerosis are shown in Figures 3 and 4. Typically, the tissue appears silvery or ivory white or blanched and shiny or crinkly (Figure 3).^{25,35} Any area from the clitoral hood to the perianal area can be affected. The labia minora, interlabial folds, clitoris, clitoral hood, and perineal body are most frequently involved; the perianal area also is involved in 60% of cases.³⁵ Lichen sclerosis does not affect the vagina. There may be one small area of white epithelium, or it may cover the vulva, in patches or confluent. Often symmetrical, there may be a

Box 1. Lichen Sclerosis

A 63 year old woman reports one month of vulvar itching. After taking antibiotics, she thought she had a yeast infection and treated herself with an antifungal cream; her symptoms improved but then returned. She has no discharge or odor. She wears pantliners daily because of urinary leaking but uses no other vulvar products. Her medical history is significant for Lyme disease. She is not currently sexually active due to her husband's health issues. On exam her vulvar anatomy is normal and she is found to have a pale area on the right labia minora. Wet prep and yeast culture are negative. Avoidance of contact irritants is discussed, and a biopsy is recommended, which she declines. She returns a few months later with persistent itching, and she requests a biopsy. An exam shows multiple patches of white epithelium on the labia minora and sulcus. A biopsy is performed and the pathology report shows lichen sclerosis. She is started on clobetasol ointment 0.05% nightly until her follow up visit 2 months later. At that time her symptoms have resolved and the white epithelium has faded. She is advised to continue using the clobetasol ointment 3 times a week for a month, then 1–2 times a week for maintenance. When she is seen 6 months later she is feeling much better, has stopped the clobetasol and is using A&D ointment and vitamin E oil. She is instructed to resume using the clobetasol ointment at least once a week to prevent symptom flares, disease progression and scarring, and follow up in 6 months is scheduled.

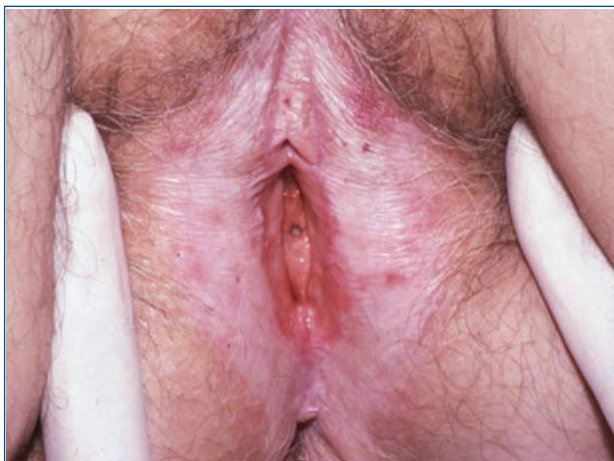

Figure 3. Lichen Sclerosus
Note the crinkly white epithelium, fusion of labia minora and labia majora, and scarred clitoral hood.

Reprinted with permission from Lynette J. Margesson, MD.

figure-of-8 pattern over the labia and perineum (Figure 4). In early stages, the characteristic changes may be minimal and subtle. With longstanding disease, thickened white plaques may predominate, or there may be significant vulvar architectural changes with less obvious or absent white epithelial changes that are inactive or “burned out.”

Secondary skin changes can occur from chronic scratching and the disease itself. Areas of swelling, purpura from subepithelial hemorrhage, excoriation, hypertrophy (thickening), and fissuring may be present.³⁷ Erosion usually is not present in lichen sclerosus unless caused by significant scratching or if VIN or cancer is present. Superimposed infection from yeast or normal skin organisms such as *Staphylococcus* or *Streptococcus* can result from scratching and disruption of the skin’s barrier function.

As lichen sclerosus progresses, scarring and loss of normal vulvar architecture occur, and this clinical finding is characteristic of lichen sclerosus. The labia minora may thin and become adherent to the labia majora, or the labia minora and majora may agglutinate and fuse entirely (Figure 3). The cli-

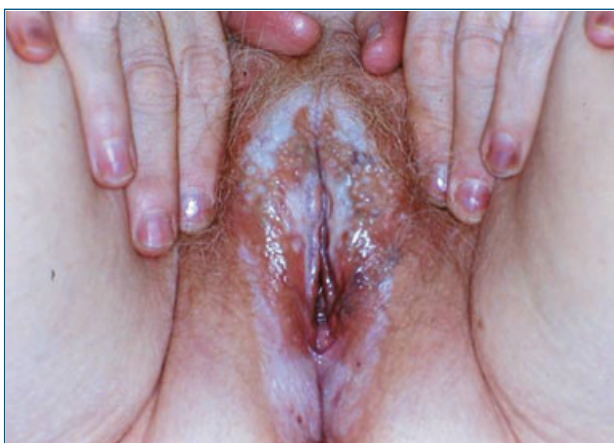

Figure 4. Lichen Sclerosus
Note the “figure 8” configuration of white epithelium plaques.

Reprinted with permission from Lynette J. Margesson, MD.

toral hood may flatten, become immobile, and, in later stages, fuse entirely so that the clitoral glans is buried under the clitoral hood, although palpable under the scar.³⁵ Scarring in an asymptomatic woman suggests lichen sclerosus, and evaluation is indicated. Rarely, in very advanced cases, there can be extensive midline agglutination that can cause introital stenosis and/or urethral obstruction and urinary retention, requiring emergency treatment.

While lichen sclerosus is the most common vulvar condition presenting with white epithelium, white areas also can be seen in women with lichen planus, vitiligo, VIN, and lichen simplex chronicus.² The differential diagnosis of lichen sclerosus is listed in Table 4.

Biopsy

A biopsy is necessary to make or confirm the diagnosis of lichen sclerosus. Lichen sclerosus is a chronic progressive condition requiring lifelong therapy and follow-up, and a biopsy is important before obligating a woman to this. There is also a 2% to 5% risk of vulvar cancer in women with lichen sclerosus, and a biopsy is important to provide women with accurate information about the risk.³⁸

Treatment of Lichen Sclerosus

Once the diagnosis has been confirmed, the goals of treatment for lichen sclerosus are to treat the woman’s symptoms if she is symptomatic; prevent disease progression and scarring or further scarring, as treatment cannot reverse scarring that has occurred already; and provide long-term follow-up and surveillance for vulvar cancer. In the 1970s and 1980s, lichen sclerosus was treated with topical testosterone,³⁹ whose androgenic side effects included clitoromegaly, acne, and facial hair.⁴⁰ A 1994 study found that topical testosterone was no more effective than petroleum jelly⁴¹ and should not be used.

Topical steroids are the treatment of choice for lichen sclerosus.^{16,25,35} A superpotent corticosteroid such as clobetasol 0.05% or halobetasol 0.05% ointment often is needed at the outset to treat thickened lichenified skin and control itching, and it is commonly used for maintenance therapy as well.⁴² These and some of the other medications recommended in this article are off-label but are supported by the current literature and vulvar specialists (Box 2). For initial treatment, clobetasol 0.05% ointment is used nightly for 8 to 12 weeks, applied sparingly to the areas of white epithelium and scarring. Once symptoms resolve, the woman can gradually taper to a maintenance regimen, usually 1 to 3 times a week.

Even when symptoms resolve, women need to continue using their ointment at least once a week as maintenance. Lichen sclerosus is a chronic disease, and lifelong use of the steroid ointment at least weekly is necessary in most women to prevent symptom recurrence and progression of vulvar scarring. Studies have shown the long-term safety of superpotent steroids for maintenance therapy.^{43,44} Women also may be switched to a mid potency corticosteroid ointment such as mometasone 0.1% ointment, based on response and preference. Mometasone has a longer half-life than other steroid ointments of its class and can be effective for lichen sclerosus.^{45,46} Women who are asymptomatic when lichen sclerosus is diagnosed but have biopsy-proven lichen sclerosus with

Table 4. Differential Diagnosis of Lichen Sclerosus, Lichen Planus, and Lichen Simplex Chronicus		
Lichen Sclerosus	Lichen Planus	Lichen Simplex Chronicus
Lichen planus	Lichen sclerosus	Lichen sclerosus
Lichen simplex chronicus	Lichen simplex chronicus	Lichen planus
Contact dermatitis	Plasma cell (zoon) vulvitis	Contact dermatitis
Vulvovaginal candidiasis	Lichenoid drug reaction	Vulvovaginal candidiasis
Vulvar psoriasis	Vulvar psoriasis	Vulvar psoriasis
Anal fissures	Anal fissures	Anal fissures
Herpes simplex	Herpes simplex	Herpes simplex
VIN	VIN	VIN
Vulvar cancer	Vulvar cancer	Vulvar cancer
Cicatricial pemphigoid	Cicatricial pemphigoid	Seborrheic/atopic dermatitis
Pemphigus vulgaris	Pemphigus vulgaris	
Paget disease	Paget disease	
Labial adhesions (in child)	Lupus	
Vitiligo	Toxic epidermal necrolysis/Stevens-Johnson syndrome	
Morphea	Fixed drug reaction	
Atrophic vaginitis/estrogen deficiency	Erythema multiforme	
Normal variant		

Abbreviation: VIN, vulvar intraepithelial neoplasia.
Sources: Stewart³; Pipkin⁴; McPherson and Cooper.⁴⁴

architectural abnormalities should be treated with clobetasol or a mid potency steroid ointment once a week and followed as for symptomatic lichen sclerosus.

Other treatment measures include avoidance of irritants as previously discussed; and culture and treat for yeast if indicated. Treat secondary bacterial skin infection if indicated with oral cephalexin (Keflex) or cefadroxil (Duricef) 500 mg twice a day for 5 days (azithromycin if the woman is penicillin allergic); oral fluconazole (Diflucan) 150 mg on the last day of antibiotics is suggested to prevent yeast vaginitis. If there is significant nighttime itching, consider an oral antihistamine.

Box 2. Off-label Uses for Medications

- Clobetasol 0.05% ointment (Temovate) for lichen sclerosus
- Halobetasol 0.05% ointment (Ultravate) for lichen sclerosus
- Mometasone furoate 0.1% ointment (Elocon) for lichen sclerosus, lichen simplex chronicus
- Prednicarbate 0.05% ointment (Dermatop) for perianal lichen sclerosus
- Hydrocortisone 2.5% ointment (Hytone) for perianal lichen sclerosus
- Iodoquinol-hydrocortisone (Vytone) for perianal lichen sclerosus
- Tacrolimus (Protopic) for lichen planus, lichen simplex chronicus
- Hydrocortisone acetate 25 mg suppository, vaginal for lichen planus
- Hydrocortisone cream 100 mg/g, vaginal, for lichen planus
- Pimecrolimus (Elidel) for lichen simplex chronicus
- Fluoxetine (Prozac) for lichen simplex chronicus
- Citalopram (Lexapro) for lichen simplex chronicus

Most women with lichen sclerosus experience complete or partial relief of symptoms with treatment, and the prognosis overall is favorable. In one study, 66% of women were symptom-free after 3 months of treatment with a superpotent corticosteroid ointment.³⁶ Another study showed complete remission in 54% of women; however, the older a woman was, the less likely she was to experience this.⁴⁷ Scarring that has already occurred is not reversible, but progression of scarring may be prevented with long-term steroid use. Women who respond to initial treatment can have symptom recurrences or “flares,” spontaneously or provoked. If a woman experiences increased itching or irritation, she should use the steroid ointment daily for a few days, up to a week, and resume her maintenance regimen as symptoms abate. If symptoms persist, she should be evaluated to rule out yeast, secondary infection, or some other problem that may be causing the flare.

Perianal lichen sclerosus can be very difficult to manage. Stool is a strong vulvar irritant, and diarrhea can cause flares. Constipation can cause the sensitive skin around the anus affected by lichen sclerosus to split. Women tend to aggressively cleanse after bowel movements, and this can worsen symptoms. For gentle toilet hygiene, mineral oil can be used; see Table 2 and Vulvar Care Guidelines (Share with Women) for other suggestions. If a woman has bowel problems due to disease or medication, she may need to see her primary health care provider or a gastroenterologist to address this. The perianal folds are more susceptible to thinning from superpotent steroid ointments than the rest of the vulva.³ For severe symptoms, a thin film of clobetasol can be used but only for a strictly limited time—2 weeks at most. Then it is necessary to switch to a less potent corticosteroid, such as mometasone 0.1% ointment, prednicarbate 0.1% ointment, or hydrocortisone 2.5% ointment for long-term use in that area. Iodoquinol-hydrocortisone (Vytone), a combination mild

steroid and antibacterial cream with antifungal properties, can be used as needed in the perianal area.

If a woman's symptoms do not improve, she should be reevaluated. Consider whether she is following the treatment or whether she has another condition. Referral to a vulvar specialist is recommended for lichen sclerosus that does not respond to treatment. Thick plaques may improve with intralesional steroids and other medications that a specialist can give.^{47,48} Rarely, surgery may be indicated for selected patients with very severe scarring that affects urinary or sexual function.⁴⁹

Follow-up

After treatment is initiated, a follow-up visit is suggested in 8 to 12 weeks to evaluate response. When symptoms stabilize, women should be seen approximately every 6 months to monitor symptoms, disease progression, and for vulvar cancer surveillance. Women also should be seen as needed for symptom flares. Observe for progressive vulvar scarring, and reinforce the importance of maintenance steroid treatment to prevent this. Watch for introital stenosis from scarring, especially in older women. Women who are not sexually active may need to use a dilator to preserve vaginal patency.

While lichen sclerosus is not considered a precancerous condition, about 2% to 5% of women with lichen sclerosus develop vulvar cancer—primarily squamous cell carcinoma—although verrucous carcinoma, basal cell carcinoma, malignant melanoma, and VIN also have been reported.^{15,24,50,51} Any new or suspicious lesion, ulceration, or nodule should be biopsied if persistent.⁹ It is important to let the woman know that she does not have cancer, but discuss the risk of vulvar cancer and need for regular surveillance.

Box 3. Lichen Planus

A 54 year old woman is seen for a complaint of one year of vulvar burning, soreness, intermittent intense itching, and dyspareunia. She has been unable to have intercourse for 8 months. She has tried several topical medications including vaginal estrogen cream, KY jelly, and Replens, without improvement. She has been using A&D ointment for comfort. When she is asked about mouth problems, she notes that she has a history of oral lichen planus for 15 years and has not been treated for this. On oral exam she has an eroded area on her bottom gum line with erythema and ulceration. On pelvic exam she has glazed erythema in a horseshoe pattern surrounding her introitus. There is clitoral scarring and the clitoral glans is not visible. She has mild introital narrowing, no erosions seen over the vagina, and normal length of vagina is noted. Given her oral disease, a biopsy is not done, and she is diagnosed with erosive oral and vulvovaginal lichen planus. She is treated with a dose of 70 mg IM triamcinolone in clinic, followed by topical clobetasol 0.05% ointment nightly and 10 mcg vaginal estradiol tablets (Vagifem) twice weekly. Follow up is scheduled in 3 months and she is referred to a dermatologist for treatment of her oral disease.

LICHEN PLANUS

Lichen planus (see Box 3) is an inflammatory mucocutaneous skin condition that is much less common than lichen sclerosus. It was first described in 1867, although not mentioned in any gynecologic text until the 1940s. It is a mucous membrane disease that can involve the skin, oral cavity, genital mucous membranes, scalp, and nails. The vulva or vagina may be affected as part of a widespread generalized skin eruption or in isolation. Fifty percent of women with cutaneous lichen planus also have genital involvement.⁵² It is important to ask about gum problems, skin rashes, and alopecia when lichen planus is suspected. Esophageal involvement is found rarely.⁵³

The etiology of lichen planus is unknown; it is an autoimmune disorder in which activated T cells are directed against basal keratinocytes.⁵⁴ Like lichen sclerosus, vulvovaginal lichen planus is associated with other autoimmune diseases.²⁹ Lichen planus usually is seen in women who are perimenopausal or postmenopausal, but it occasionally can affect younger women. Unlike lichen sclerosus, lichen planus is seen in children rarely. Lichen planus can affect the vulva and the vagina, whereas lichen sclerosus does not affect the vaginal epithelium. There is a risk of vulvar cancer with lichen planus; the incidence is unknown, but small retrospective studies have found an incidence of 3% to 6%.^{55,56}

Symptoms of Lichen Planus

The most common symptom of lichen planus is vulvovaginal soreness, burning, or itching.³⁴ Women with lichen planus are rarely asymptomatic. Women often complain of dyspareunia, dysuria, and/or vaginal discharge.⁴ Sore gums and skin lesions can be present when there is disease beyond the genital region.

Examination

The appearance of lichen planus can vary. The most common form seen in the vulva is the erosive type of lichen planus, with erosions presenting over the vestibule surrounding the introitus. The vulvar tissue appears bright red ("glazed erythema"), is often denuded, and is extremely tender to touch. There may be a characteristic lacy white edge to the erosions and a violaceous color change at the border of the involved epithelium.⁵⁴ In addition, there can be loss of vulvar architecture similar to that in lichen sclerosus, with agglutination of the labia minora, phimosis, scarring of the clitoris, and midline agglutination resulting in introital narrowing. When these architectural changes are present without active erosive disease, it can be difficult to distinguish lichen planus from advanced lichen sclerosus. Papulosquamous lichen planus is less common; it presents with white epithelium and small pruritic red papules. See Figure 5 for an example of the appearance of lichen planus.

When there is vaginal involvement, there can be vaginal erosions and synechia. An irritating vaginal discharge also can be present. Often there is vaginal stenosis with loss of the normal vaginal length, and this can be present without any other active disease seen in the vagina or over the vulva. The shortening of the vagina can be asymptomatic unless the patient tries to have intercourse or insert a tampon. The differential diagnosis of lichen planus is listed in Table 4.

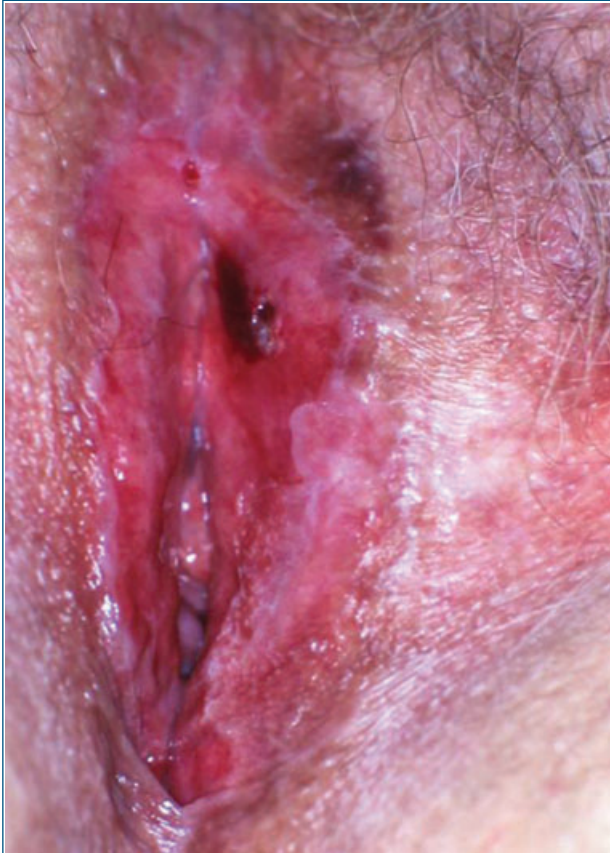

Figure 5. Lichen Planus
Note the violaceous border with the characteristic lacy appearance.

Reprinted with permission from Lynette J. Margesson, MD.

Diagnosis of Lichen Planus

A biopsy usually is required for diagnosis, unless classic erosions are seen in a woman who has already been diagnosed with oral or cutaneous lichen planus. When a biopsy is performed on an area of erosion, it is important to biopsy the edge so that a small area of normal tissue is included. A biopsy of the vaginal tissue usually is not performed unless an area of erosion is seen in the absence of vulvar disease. If an abnormal vaginal discharge is seen in a patient with lichen planus, it is usually inflammatory, showing many white blood cells and immature squamous (parabasal) cells, along with an elevated pH.

Treatment of Lichen Planus

Treatment of erosive lichen planus is usually more difficult than treatment of lichen sclerosus. Collaborative management with or referral to a vulvar specialist usually is required. If there are symptoms in the mouth or oral disease is seen, referral to a dermatologist is recommended.

Treatment usually is started with nightly use of a super-potent steroid such as clobetasol 0.05% or halobetasol 0.05% ointment.⁵⁷ Comfort care with tub baths and petroleum jelly can be extremely helpful, and avoidance of all irritants as described previously is important. Once the woman's condition stabilizes with clobetasol, tacrolimus (Protopic) may be introduced; this is a macrolide immunosuppressive agent used

Box 4. Lichen Simplex Chronicus

A 22 year old woman who was treated for a yeast infection six months ago comes in with a complaint of intense perianal and vulvar itching, no discharge. She cannot help scratching and it keeps her up at night. She denies using pads, pantliners, wipes, new soap or detergent, or any other products. She has no skin problems but reports sensitivity to some earrings. Her medical history is significant for mild anxiety; she has had no gynecological problems or STDs. She takes birth control pills and is not currently in a relationship or sexually active. On exam, the labia minora are swollen and erythematous, labia majora are pale and leathery with multiple areas of excoriation; the perineum is hypertrophic with fissures and there is extensive excoriation surrounding perianal area. Wet prep and yeast culture are negative. Clinical assessment is lichen simplex chronicus. She is treated with clobetasol 0.5% ointment, twice daily for two weeks, then once daily for 2 weeks, followed by 3 times a week until the follow-up appointment. A superimposed bacterial skin infection is treated with cephalexin (Keflex) 500 mg po twice a day for 5 days with one 150 mg fluconazole tablet on day 5. She is given hydroxyzine 10 mg orally as needed for nighttime itching. She is instructed to avoid all irritants and do warm soaks followed by an application of petroleum jelly. When she is seen 3 months later her symptoms have almost completely resolved. Her exam shows a normal vulva with mild hypertrophy in the perianal area. She is given mometasone 0.1% ointment to use as needed for symptom recurrence and follow-up is scheduled in 6 months.

in the treatment of eczema that can be a useful maintenance treatment for lichen planus,⁵⁸ although irritation limits its effectiveness. If a woman does not respond to topical treatment, systemic therapy must be considered, and referral to a vulvar specialist is indicated.

For vaginal involvement with erosive disease, corticosteroids are used intravaginally. For mild involvement, 25 mg hydrocortisone acetate suppositories can be inserted intravaginally.⁵⁹ For more extensive disease, high-dose hydrocortisone cream (100 mg/g) can be compounded by a specialized pharmacy for vaginal use (1-3 g nightly). Referral to a vulvar specialist is recommended for vaginal disease. Vaginal shortening without active disease may require surgical lengthening with postoperative use of vaginal dilators and high-dose topical intravaginal steroid therapy to maintain vaginal patency.

The prognosis for lichen planus is variable, but studies suggest that 54% to 66% of women have improvement in symptoms with superpotent steroid treatment.^{56,60} Although collaboration with or referral to a vulvar specialist is generally necessary, emotional support is very important for women with this chronic, often painful disease with accompanying sexual dysfunction and need for long-term treatment.

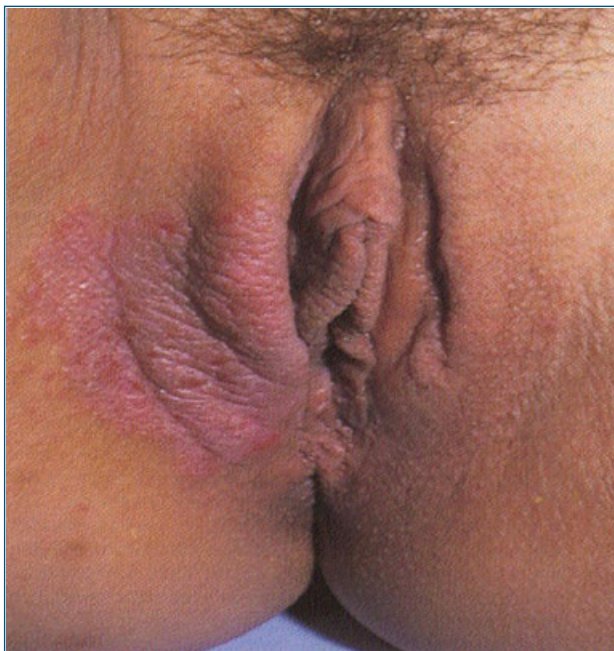

Figure 6. Lichen Simplex Chronicus
Note the characteristic thickened, leathery appearance of the vulva.

Reprinted with permission from Lynette J. Margesson, MD.

LICHEN SIMPLEX CHRONICUS

Lichen simplex chronicus (see Box 4) is a skin condition that affects many areas of the body including the vulva. It is characterized by a cycle of itching that leads to scratching, which causes more itching. Chronic scratching or rubbing in response to itching that may be caused by a number of conditions results in hypertrophy and lichenification of the

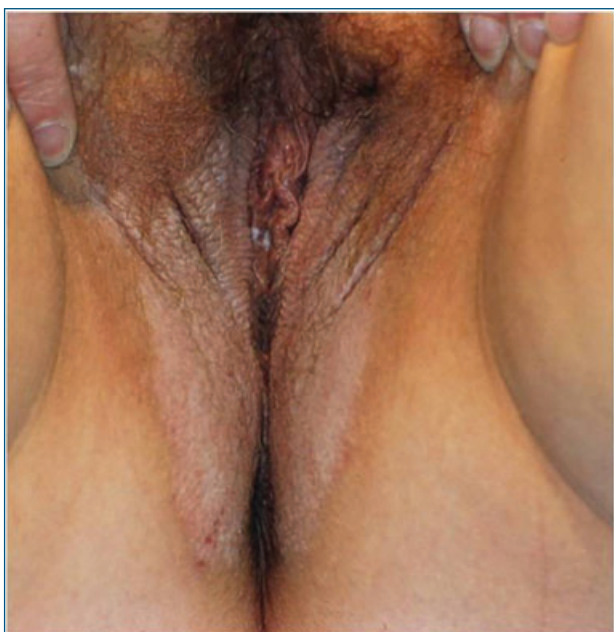


Figure 7. Lichen Simplex Chronicus
Note the leathery, hypertrophic tissue, which is pale but not as white as seen with lichen sclerosis.

Reprinted with permission from Lynette Margesson, MD.

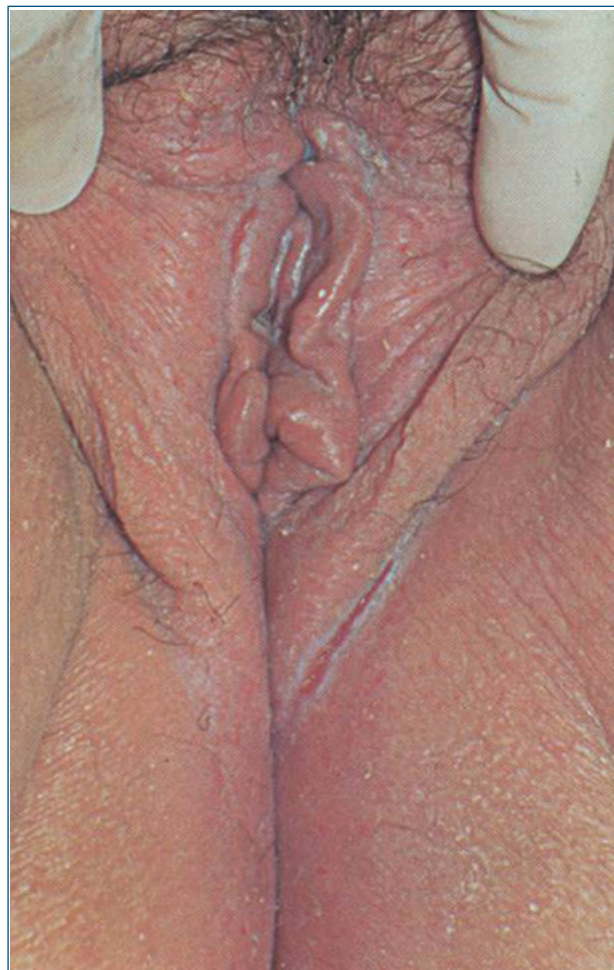

Figure 8. Lichen Simplex Chronicus
Note edematous labia and fissuring on the labial sulcus and perineum.

Reprinted with permission from Lynette J. Margesson, MD.

vulva, which causes more itching, more scratching, resulting in an often refractory itch-scratch-itch cycle.⁶¹ The damaged skin loses its protective barrier function, making it susceptible to superimposed infection, which is not uncommon with lichen simplex chronicus.

Lichen simplex chronicus is common, but the actual incidence is unknown. Anogenital lichen simplex chronicus is estimated to occur in as many as 5% of all Western European and American adults; it affects women more than men and accounts for 10% to 35% of women seen in specialty vulvar clinics.⁶¹ The original cause of the itching may or may not be present when a woman is evaluated. These include contact dermatitis from vulvar irritants (Table 2); vulvovaginal candidiasis, often undiagnosed; lichen sclerosus, vulvar psoriasis, VIN and other vulvar conditions. Atopic dermatitis (eczema) also can trigger lichen simplex chronicus. Many women with lichen simplex chronicus have a personal or immediate family history of atopy, such as allergies, asthma, eczema, and sensitivities to jewelry and other agents.

Symptoms of Lichen Simplex Chronicus

The primary symptom of lichen simplex chronicus is itching, often intractable and uncontrollable, sometimes developing

into burning and pain.³ Symptoms can be intermittent or chronic and may have been present for weeks, months, or even years. Symptoms tend to worsen with heat, humidity, and contact with menses, urine, stool, medications, and vulvar products and hygiene. Scratching relieves itching and may be difficult to control. Itching is often better on waking but worsens during the day and at night, which can interfere with sleep.³

Examination

Lichen simplex chronicus can affect the entire vulva and perianal area or part of it. It may be localized, bilateral, or unilateral. See Figures 6, 7, and 8 for examples of the varied appearance of lichen simplex chronicus. The vulvar skin thickens so that normal skin markings are accentuated, and the tissue appears leathery or lichenified or it may be pale and wrinkled, as if having been in water too long⁶¹ (Figures 6 and 7). Labial swelling and erythema can be present (Figure 8). The color varies from pink or dusky to red or purple, and there may be pale hypopigmented areas, although not as white as with lichen sclerosus (Figure 7). Darkened areas of post-inflammatory hyperpigmentation also may be present. Excoriation from scratching is common, and there can be painful fissures at the natural skin folds or elsewhere as well as erosions, ulcerations, and crusting⁶¹ (Figure 8). There may be hair loss in some areas caused by scratching. Unlike lichen sclerosus and lichen planus, there is no scarring associated with lichen simplex chronicus unless an underlying dermatosis is present.

A yeast culture from the vagina and the affected areas of the vulva should be obtained, as yeast vaginitis may be an underlying cause of lichen simplex chronicus. These women often do not have the typical signs of vulvovaginal candidiasis, and microscopy has a low sensitivity and specificity.^{6–8} Areas of fissuring, excoriation, or other vulvar skin breakdown should be swabbed and sent for yeast and bacterial cultures. A bacterial culture of the vaginal walls or discharge is not useful.

Diagnosis

Diagnosis of lichen simplex chronicus usually is made by clinical examination. A biopsy should be done only if the diagnosis cannot be determined by visual inspection or if indicated when skin changes due to lichen simplex chronicus have resolved. The differential diagnosis of lichen simplex chronicus is listed in Table 4.

Treatment of Lichen Simplex Chronicus

The goal of treatment for lichen simplex chronicus is to stop the itch-scratch-itch cycle and heal the vulvar skin. This requires all of the following: elimination of all vulvar irritants, stopping the itching-scratching cycle, treating any underlying disease and/or coexisting infections, decreasing inflammation, and correcting the skin's barrier function.¹¹ While lichen simplex chronicus often responds to treatment and the prognosis is good, improvement can take time, and recurrences are common. Women's self-care and habits are key factors in treatment effectiveness and prevention of recurrences.

Elimination of all contact irritants as addressed earlier is essential in the treatment and prevention of lichen simplex chronicus. If urinary incontinence or bowel problems are contributing factors, these should be addressed; a referral to a specialist for these may be needed.

Topical corticosteroid ointments are prescribed for lichen simplex chronicus to reduce itching and inflammation, and, for most women, superpotent steroids are needed initially because of the intensity of the symptoms and hypertrophic vulvar tissue. Clobetasol 0.05% or halobetasol 0.05% ointment is applied to affected areas sparingly, as previously described, 1 to 2 times a day for 2 weeks, then daily for an additional 2 to 4 weeks, depending on the response. This is followed by tapering steroid use to 2 to 3 times a week until the follow-up visit. A mid potency ointment such as mometasone 0.1% also may be used for milder symptoms. Some women have such severe lichen simplex chronicus that any topical ointment causes burning, and in selected cases, intramuscular triamcinolone (60–80 mg, depending on the woman's weight) can be useful for immediate symptom relief.⁶⁴ This should be given only in collaboration with a clinician experienced with this medication's effects, side effects, and contraindications (eg, diabetes, adrenal disease, severe depression, other psychiatric illnesses). Intralesional triamcinolone also is used by vulvar specialists for women who have thickened plaques or are unable to use topical medications.^{48,49} Pimecrolimus (Elidel) and tacrolimus (Protopic) also are useful in some cases.

Scratching must be avoided, and women with nighttime itching should be given an oral antihistamine for sedation. For women with daytime itching or for those who cannot tolerate antihistamine sedatives, other options include selective serotonin reuptake inhibitor antidepressants such as fluoxetine (Prozac) or citalopram (Celexa).¹¹

If there is significant fissuring, excoriation, or other signs of bacterial skin infection, a bacterial culture should be obtained from these sites. Treat if indicated by clinical findings or for growth of group B *Streptococcus* on skin culture⁶⁵ with cephalexin (Keflex) or cefadroxil (Duricef) 500 mg orally twice a day for 5 days (azithromycin if the woman is penicillin allergic), with 150 mg fluconazole (Diflucan) orally to be taken on day 5.

When the skin's barrier function is disrupted, stimulation of exposed nerve endings adds to the itching and discomfort.⁶¹ To restore the skin's barrier function and for comfort, a "soak and seal" is recommended: the woman soaks twice a day in a lukewarm sitz bath or with a washcloth for 5 to 10 minutes, pats dry, then seals in the moisture with petroleum jelly. The moisture reduces nerve signaling, and the petroleum jelly seals in the moisture. As symptoms improve, the woman can discontinue the soaks, but petroleum jelly can be used anytime.

Follow-up, Referral, and Education

A follow-up visit should be scheduled in 8 to 12 weeks to evaluate response to treatment; women should be seen sooner if needed. Symptoms and vulvar skin changes often resolve completely with adherence to recommendations and treatment, but lichen simplex chronicus also can be recurrent or persistent. Unlike lichen sclerosus and lichen planus,

lichen simplex chronicus is not a chronic progressive disease and does not require continued surveillance if the woman is asymptomatic. Referral to a vulvar specialist is recommended for women with severe or persistent symptoms that require treatment beyond the clinician's scope of care. As with other vulvar conditions, education is essential, and written instructions will help the woman remember her treatment regimen.

CONCLUSION

Lichen sclerosus, lichen planus, and lichen simplex chronicus are vulvar conditions that affect women in significant ways. Midwives and other clinicians who provide gynecological care are likely to see women with these conditions. A thoughtful and comprehensive approach as detailed in this article will greatly benefit these women and the care they receive.

AUTHORS

Katrina Alef Thorstensen, CNM, MSN, is a certified nurse-midwife and assistant professor of clinical obstetrics and gynecology at Dartmouth-Hitchcock Medical Center in Lebanon, New Hampshire. She has been a clinician in the vulvar clinic at Dartmouth-Hitchcock Medical Center since 2006.

Debra L. Birenbaum, MD, is a board-certified obstetrician-gynecologist and assistant professor of obstetrics and gynecology at Dartmouth Hitchcock Medical Center in Lebanon, New Hampshire. She started the vulvar clinic at Dartmouth Hitchcock Medical Center in 1996.

CONFLICT OF INTEREST

The authors have no conflicts of interest to disclose. The authors have no affiliations with any of the brands or products referred to in this article.

ACKNOWLEDGMENT

The authors acknowledge and thank Dr. Lynette J. Margesson for her knowledge and expertise in vulvar dermatology, her generosity in sharing it, and her commitment to women and their health care. No grants, subsidies, or financial reimbursements were provided to the authors for the preparation of this manuscript.

SUPPORTING INFORMATION

Additional supporting information may be found in the online version of this article:

Questionnaire S1: A sample questionnaire used by a referral vulvar clinic.

Please note: Wiley-Blackwell is not responsible for the content or functionality of any supporting information supplied by the authors. Any queries (other than missing material) should be directed to the corresponding author for the article.

REFERENCES

1. Danby CS, Margesson LJ. Approach to the diagnosis and treatment of vulvar pain. *Dermatol Ther.* 2010;23(5):485-504.
2. Margesson LD. Vulvar disease pearls. *Dermatol Clin.* 2006;24(2):145-155.
3. Stewart KM. Clinical care of vulvar pruritus, with emphasis on one common cause, lichen simplex chronicus. *Dermatol Clin.* 2010;28(4):669-680.
4. Pipkin C. Erosive diseases of the vulva. *Dermatol Clin.* 2010;28:737-751.
5. Schlosser BJ, Mirowski GW. Approach to the patient with vulvovaginal complaints. *Dermatol Ther.* 2010;23(5):438-448.
6. Nyirjesy P, Seeney SM, Grody MH, Jordan CA, Buckley HR. Chronic fungal vaginitis: the value of cultures. *Am J Obstet Gynecol.* 1995;173(3 pt 1):820-823.
7. Schaaf VM, Perez-Stable EJ, Borchardt K. The limited value of symptoms and signs in the diagnosis of vaginal infections. *Arch Intern Med.* 1990;150(9):1929-1933.
8. Abbott J. Clinical and microscopic diagnosis of vaginal yeast infection: a prospective analysis. *Ann Emerg Med.* 1995;25(5):589-591.
9. Maclean AB, Jones RW, Scurry J, Neill S. Vulvar cancer and the need for awareness of precursor lesions. *J Low Genit Tract Dis.* 2009;13(2):115-117.
10. Farage M, Maibach HI. The vulvar epithelium differs from the skin: implications for cutaneous testing to address topical vulvar exposures. *Contact Dermatitis.* 2004;51(4):201-209.
11. Margesson LM. Contact dermatitis of the vulva. *Dermatol Ther.* 2004;17(1):20-27.
12. Eason EL, Feldman P. Contact dermatitis associated with the use of Always sanitary napkins. *CMAJ.* 1996;154(8):1173-1176.
13. Marin MG, King R, Sfameni S, Dennerstein GJ. Adverse behavioral and sexual factors in chronic vulvar disease. *Am J Obstet Gynecol.* 2000;183(1):34-38.
14. Ference JD, Last AR. Choosing topical corticosteroids. *Am Fam Physician.* 2009;15;79(2):135-140.
15. Dalziel KI. Effect of lichen sclerosus on sexual function and parturition. *J Reprod Med.* 1995;40(4):351-354.
16. Neill SM, Lewis FM, Tatnall FM, Cox NH. British Association of Dermatologists' guidelines for the management of lichen sclerosus 2010. *Br J Dermatol.* 2010;163(4):672-682.
17. Thomas RH, Ridley CM, McGibbon DH, Black MM. Anogenital lichen sclerosus in women. *JR Soc Med.* 1996;89(12):694-698.
18. Goldstein AT, Marinoff SC, Christopher K, Srodon M. Prevalence of vulvar lichen sclerosus in a general gynecology practice. *J Reprod Med.* 2005;50(7): 477-480.
19. Jones RW, Scurry J, Neill S, MacLean AB. Guidelines for the follow-up of women with vulvar lichen sclerosus in specialist clinics. *Am J Obstet Gynecol.* 2008;198(5):496.e1-3.
20. Leibovitz A, Kaplun V, Saposhnikov N, Habot B. Vulvovaginal examinations in elderly nursing home residents. *Arch Gerontol Geriatr.* 2000;31(1):1-4.
21. Smith SD, Fischer G. Paediatric vulval lichen sclerosus. *Australas J Derm.* 2009;50(4):243-248.
22. Sherman V, McPherson T, Baldo M, Salim A, Gao XH, Wojnarowska F. The high rate of familial lichen sclerosus suggests a genetic contribution: an observational cohort study. *J Eur Acad Dermatol Venereol.* 2010;29(9):1031-1034.
23. Eisendie K, Grabner T, Kutzner H, Zelger B. Possible role of Borriela burgdorferi sensu lato infection in lichen sclerosus. *Arch Dermatol.* 2008;144(5):591-598.
24. Farrell AM, Millard PR, Schomberg KH, Wojnarowska F. An infective aetiology for lichen sclerosus re-addressed. *Clin Exp Dermatol.* 1999;24(6):479-483.
25. Murphy R. Lichen sclerosus. *Dermatol Clin.* 2010;28(4):707-715.
26. Howard A, Dean D, Cooper S, Kirtshig G, Wojnarowska F. Circulating basement membrane zone antibodies are found in lichen sclerosus of the vulva. *Australas J Dermatol.* 2004;45(1):12-15.
27. Oyama N, Chan I, Neill SM, Hamada T, et al. Autoantibodies to extracellular matrix protein 1 in lichen sclerosus. *Lancet.* 2003;362(9378):118-1123.
28. Gao XH, Bernardo MC, Winsey S, et al. The association between HLA DR, DQ antigens, and vulval lichen sclerosus in the UK:

- HLA DRB1*12 and its associated DRB1* 12/DQB1*0301/04/09/010 haplotype confers susceptibility to vulval lichen sclerosis, and HLA DRB1*0301/04 and its associated DRB1*0301/04/DQB1*0201/02/03 haplotype protects from vulval lichen sclerosis. *J Invest Dermatol.* 2005;125(5):895-899.
29. Meyrick Thomas RH, Ridley CM, McGibbon DH, Black MM. Lichen sclerosis et atrophicus and autoimmunity—a study of 350 women. *Br J Dermatol.* 1988;118(1):41-46.
30. Cooper SM, Ali I, Baldo M, Wojnarowska F. The association of lichen sclerosis and erosive lichen planus of the vulva with autoimmune disease: a case-control study. *Arch Dermatol.* 2008;144(11):1432-1435.
31. Birenbaum D, Young RC. High prevalence of thyroid diseases in patients with lichen sclerosis. *J Reprod Med.* 2007;52(1):28-30.
32. Hodgins MB, Spike RC, Mackie RM, MacLean AB. An immunohistochemical evaluation of androgen, oestrogen and progesterone receptors in the vulva and vagina. *Br J Obstet Gynaecol.* 1998;105(2):216-222.
33. Maronn ML, Easterly NB. Constipation as a feature of anogenital lichen sclerosis in children. *Pediatrics.* 2005;115(2):230-232.
34. Marin MG, King R, Dinnerstein GI, Sfamini S. Dyspareunia and vulval disease. *J Reprod Med.* 1998;43(11):952-958.
35. McPherson T, Cooper S. Vulval lichen sclerosis and lichen planus. *Dermatol Ther.* 2010;23(5):529-532.
36. Cooper SM, Gao XH, Powell JJ, Wojnarowska F. Does treatment of vulvar lichen sclerosis influence its prognosis? *Arch Dermatol.* 2004;140(6):702-706.
37. Smith YR, Haefner HK. Vulvar lichen sclerosis: pathophysiology and treatment. *Am J Clin Dermatol.* 2004;5(2):105-125.
38. Carli P, Cutaneo A, De Magnis A, Biggeri A, Taddei G, Gianotti B. Squamous cell carcinoma arising in vulval lichen sclerosis: a longitudinal cohort study. *Eur J Cancer Prev.* 1995;4(6):491-495.
39. Friedrich EG Jr. Topical testosterone for benign vulvar dystrophy. *Obstet Gynecol.* 1971;37(5):677-686.
40. Joura EA, Zeilsler H, Bancher-Todesca D, Satro MO, Schneider B, Gitch G. Short-term effects of topical testosterone in vulvar lichen sclerosis. *Obstet Gynecol.* 1997;89(2):297-299.
41. Sideri M, Origoni M, Spinaci L, Ferrari A. Topical testosterone in the treatment of vulvar lichen sclerosis. *Int J Gynaecol Obstet.* 1994;46(1):53-56.
42. Lorenz B, Kaufman RH, Kutzner SK. Lichen sclerosis: therapy with clobetasol propionate. *J Reprod Med.* 1998;43(9):790-794.
43. Sinha P, Sorinola O, Luesley DM. Lichen sclerosis of the vulva: long term steroid maintenance therapy. *J Reprod Med.* 1999;4(7):621-624.
44. Dalziel KL, Wojnarowska F. Long-term control of vulvar lichen sclerosis after treatment with a potent topical steroid cream. *J Reprod Med.* 1993;38(1):25-27.
45. Cattaneo A, de Magnis A, Botti E, Sonni L, Carli P, Taddei GL. Topical mometasone furoate for vulvar lichen sclerosis. *J Reprod Med.* 2003;48(6):444-448.
46. Bradford J, Fischer G. Long-term management of vulval lichen sclerosis in adult women. *Aust NZ J Obstet Gynaecol.* 2010;50(2):148-152.
47. Reynaud-Vilmer C, Cavelier-Balloy B, Porcher R, Dubertret L. Vulvar lichen sclerosis: effect of long-term topical application of a potent steroid on the course of the disease. *Arch Dermatol.* 2004;140(6):709-712.
48. Mazdisnian F, Degregorio F, Palmieri A. Intralesional injection of triamcinolone in the treatment of lichen sclerosis. *J Reprod Med.* 1999;44(4):332-334.
49. Richards RN. Update on intralesional steroid: focus on dermatoses. *J Cutan Med Surg.* 2010;14(1):19-23.
50. Goldstein A, Burrows LJ. Surgical treatment of clitoral phimosis caused by lichen sclerosis. *Am J Obstet Gynecol.* 2007;196(2):126.e1-126.e4.
51. Haefner HK, Tate JE, McLachlin CM, Crum CP. Vulvar intraepithelial neoplasia: age, morphological phenotype, papillomavirus DNA, and coexisting invasive carcinoma. *Hum Pathol.* 1995;26(2):147-154.
52. Derrick EK, Ridley CM, Kobza-Black A, McKee PH, Neill SM. A clinical study of 23 cases of female anogenital carcinoma. *Br J Dermatol.* 2000;143(6):1217-1223.
53. Lewis FM, Shah M, Harrington CI. Vulval involvement in lichen planus: a study of 37 women. *Br J Dermatol.* 1996;135(1):89-91.
54. Fox LP, Lightdale CJ, Grossman ME. Lichen planus of the esophagus: what dermatologists need to know. *J Am Acad Dermatol.* 2011;65(1):175-183.
55. Moyall-Barracco M, Edwards L. Diagnosis and therapy of anogenital lichen planus. *Dermatol Ther.* 2004;17(1):38-46.
56. Cooper SM, Wojnarowska F. Influence of treatment of erosive lichen planus on the vulva and its prognosis. *Arch Dermatol.* 2006;142(3):289-294.
57. Cooper SM, Haefner HK, Abrahams-Gessel S, Margesson LJ. Vulvovaginal lichen planus treatment: a survey of current practices. *Arch Dermatol.* 2009;144(11):1520-1521.
58. Kirtschig G, Van Der Meulen AJ, Ion Lipan JW, Stoof TJ. Successful treatment of erosive vulvovaginal lichen planus with topical tacrolimus. *Br J Dermatol.* 2002;147(3):625-626.
59. Anderson M, Kutzner S, Kaufman RH. Treatment of vulvovaginal lichen planus with vaginal hydrocortisone suppositories. *Obstet Gynecol.* 2002;100(2):359-362.
60. Kirtschig G, Wakelin SH, Wojnarowska F. Mucosal vulval lichen planus: outcome, clinical and laboratory features. *J Eur Acad Dermatol Venereol.* 2005;19(3):301-307.
61. Lynch PJ. Lichen simplex chronicus (atopic/neurodermatitis) of the anogenital region. *Dermatol Ther.* 2004;17(4):8-19.
62. Crone AM, Stewart EJ, Wojnarowska F, Powell SM. Aetiological factors in vulvar dermatitis. *J Eur Acad Dermatol Venereol.* 2000;14(3):181-186.
63. Virgili A, Bacilieri S, Corazza M. Evaluation of contact sensitization in vulvar lichen simplex chronicus: a proposal for a battery of selected antigens. *J Reprod Med.* 2003;48(1):33-36.
64. Robins, D. Intramuscular triamcinolone: a safe, effective and underutilized dermatologic therapy. *J Drugs Dermatol.* 2009;8(6):580-585.
65. Herbst R. Perineal streptococcal dermatitis/disease: recognition and management. *Am J Clin Dermatol.* 2003;4(8):555-560.

Continuing education units (CEUs) for this article are offered as part of the CEU theme issue entitled Pharmacology, Part II (May/June 2012, Volume 57, Number 3). To obtain CEUs online, please visit www.jmwhce.org. A CEU form that can be mailed or faxed is available in the print edition of the theme issue.

Appendix 1. Educational Web Sites and Resources for Women

Resource	Web Site/Publisher	Description
The International Society for the Study of Vulvovaginal Disease (ISSVD)	www.issvd.org	An international organization of dermatologist and gynecologist specialists in vulvovaginal disease. Includes educational materials, referrals to vulvar specialists, and continuing education.
Worldwide Lichen Sclerosus Support (WLSS)	www.lichensclerosus.org	A British organization that has good information for women on lichen sclerosus.
New Zealand Dermatological Society	www.dermnetnz.org	Web site of the New Zealand Dermatological Society that has information about all dermatologic conditions for providers and consumers.
University of Michigan Department of Gynecology, Center for Vulvar Diseases	http://obgyn.med.umich.edu/patient-care/womens-health-library/vulvar-diseases/information	Information from the University of Michigan Gynecology Center for Vulvar Diseases and vulvar specialist, Dr. Hope Haefner. Good resource for clinicians; also has information that may be given to women.
Libby Edwards, MD, Mid-Charlotte Dermatology and Research	http://libbyedwardsmd.com/libby-edwards-handouts.htm	Handouts on vulvar and dermatologic conditions from Dr. Libby Edwards, a dermatologist and vulvar disease specialist.
<i>The V Book</i> by Elizabeth G. Stewart, MD, and Paula Spencer	Bantam Books, 2002.	An excellent book about all aspects of vulvovaginal health and conditions by one of the pioneers in the field. Although published in 2002, it is still current.