


## SHORT COMMUNICATION

## Lichen sclerosus in pregnancy: A review of 33 cases

Yvonne Nguyen<sup>1,2</sup> , Jennifer Bradford<sup>3</sup> and Gayle Fischer<sup>4,5</sup>

<sup>1</sup>Discipline of Dermatology, Sydney Medical School Central, The University of Sydney, Sydney, New South Wales, Australia

<sup>2</sup>Department of Dermatology, Royal Prince Alfred Hospital, Camperdown, New South Wales, Australia

<sup>3</sup>University of Western Sydney, Blacktown, New South Wales, Australia

<sup>4</sup>Discipline of Dermatology, Sydney Medical School Northern, The University of Sydney, Sydney, New South Wales, Australia

<sup>5</sup>Department of Dermatology, Royal North Shore Hospital, St Leonards, New South Wales, Australia

*Correspondence:* Dr Yvonne Nguyen, Dermatology Department, Level 3 Gloucester House, Royal Prince Alfred Hospital, Missenden Rd, Camperdown NSW 2050, Australia. Email: yvonne.nguyen@sydney.edu.au

*Conflict of Interest:* The authors have declared they have no conflicts of interest.

Received: 1 December 2017;  
Accepted: 12 March 2018

Vulval lichen sclerosus (VLS) is a chronic inflammatory skin condition affecting the anogenital area in women. Serious long-term consequences of VLS include the risk of developing squamous cell carcinoma of the vulva as well as of scarring and alteration of vulval architecture. The treatment of choice for genital lichen sclerosus in females is potent to very potent topical corticosteroids. There are few published data on the course of VLS in pregnancy. We present our experience of managing 33 pregnancies in 29 women with VLS.

## KEYWORDS

caesarean section, pregnancy, spontaneous vaginal delivery, topical corticosteroids, vulval lichen sclerosus

## INTRODUCTION

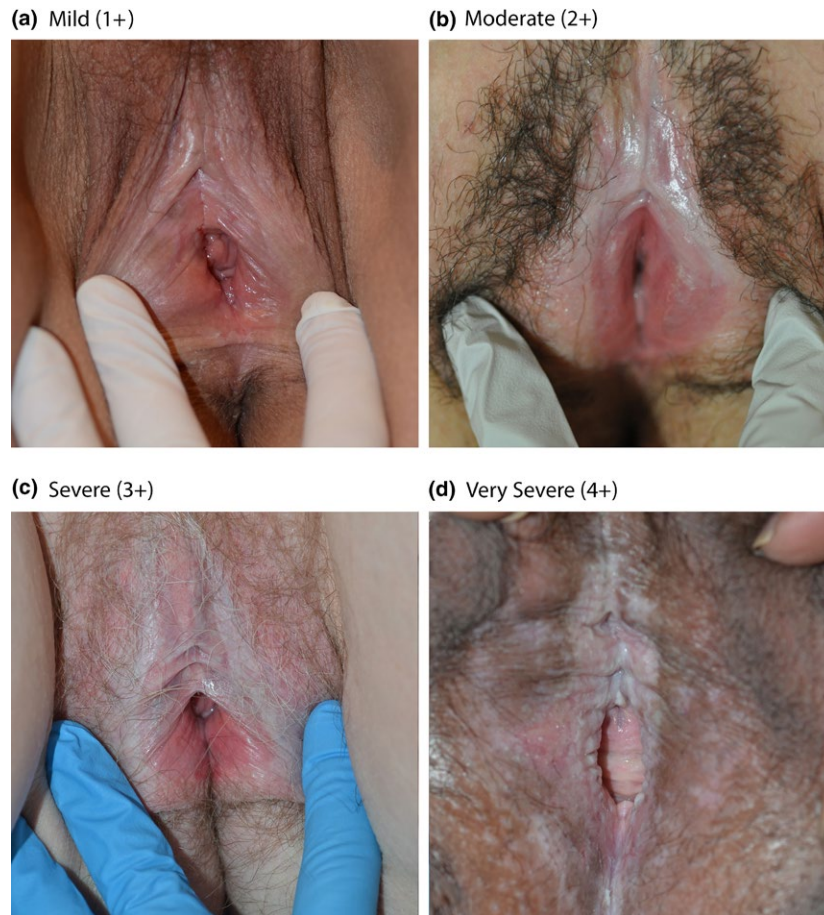Vulval lichen sclerosus (VLS) is a chronic inflammatory skin condition affecting the anogenital area in women.<sup>1</sup> Any age group may be affected, although it is more often diagnosed in older peri- or post-menopausal women.<sup>2,3</sup> The classic feature of VLS is a white plaque involving the vulva, perineum and perianal skin.<sup>4</sup> Other features include telangiectasia, hypopigmentation, purpura, erosions, fissures and oedema of the clitoral skin.<sup>5</sup> Symptoms of VLS include pruritus, which is often severe, pain and dyspareunia.<sup>1</sup> The treatment of choice for genital lichen sclerosus (LS) in females is potent to very potent topical corticosteroids.<sup>6</sup> Other treatments which have been used include testosterone, progesterone, tacrolimus and phototherapy.<sup>2</sup> Surgery in VLS is reserved for complications such as functional impairment, division of adhesions or development of pre-malignancy or malignancy.<sup>6</sup> Serious long-term consequences

of VLS include a 5% risk of developing squamous cell carcinoma of the vulva as well as a 50% risk of scarring and alteration of vulval architecture.<sup>2,6</sup>

There are few published data on the course of VLS in pregnancy.<sup>7</sup> Questions remain about possible remission during gestation, treatment during pregnancy and the disease's effect on delivery. We present our experience of managing 33 pregnancies in 29 women with VLS.

## MATERIALS AND METHODS

A retrospective, single-centre electronic database review from an outpatient dermatogynaecology practice was conducted in December 2016, in Sydney, Australia. In total 29 patients who had a total of 33 pregnancies with a biopsy-confirmed diagnosis of VLS were identified. Management was with continuous



**FIGURE 1** Visual clinical severity scale for vulvar lichen sclerosis based on grading of hyperkeratosis.

**TABLE 1** Numerical grading system for topical corticosteroid

Topical corticosteroid	Grade/relative potency
Hydrocortisone 1%	Mild/1
Methylprednisolone aceponate 0.1%	Moderate/6
Betamethasone dipropionate 0.05%	Potent/7
Betamethasone dipropionate 0.05% in optimised vehicle	Super-potent/8
Clobetasol propionate 0.05%	Ultra-potent/12

topical corticosteroid (TCS), sufficient to obtain control of signs and symptoms of disease and significant reduction in hyperkeratosis. A visual clinical severity scale for VLS based on grading of hyperkeratosis was used (Fig. 1).<sup>8</sup> TCS are commonly classed according to strength and a potency grading system based on standard definitions of TCS classes including mild, moderate, potent and ultra-potent was used to document total weekly TCS dose (Table 1). The total weekly TCS dose was calculated in numerical terms for the purpose of comparison via addition of individual daily TCS use based on the potency grading system described in Table 1 for each patient. The average use of TCS for each group of patients in

the pre-pregnancy, pregnancy and post-pregnancy groups was compared by calculating the numerical mean for the total TCS use for each group per week and are detailed in Table 2. Adequate control was defined as complete visual suppression of VLS. Good compliance was defined as always/mostly following treatment regimens based on a five-point Likert scale.<sup>8</sup> Institutional review board approval was not required for this deidentified case series however we note that all patients in the case series consented to have their clinical records used and analysed for research purposes.

## RESULTS

A total of 33 patients with VLS with concurrent pregnancy were identified and of these 12/33 (36%) had mild disease, 11/33 (33%) moderate, 8/33 (24%) severe, and 2/33 (6%) very severe disease. Of the 33, 29 women had commenced treatment prior to pregnancy and the mean duration of management before conception was 28 months (range, 1-156 months). Four women presented during pregnancy. In the patients with prior VLS average weekly TCS requirements were similar from preconception, through pregnancy to post-partum. The total weekly dose of recommended TCS was

**TABLE 2** Average weekly TCS requirements pre-, during and post-pregnancy (please refer to Table 1 for TCS grading)

Stage of Pregnancy	Total weekly dose of recommended TCS mean (range) <sup>†</sup>
Pre-pregnancy	21.5 (0–84)
Pregnancy	21.8 (0–112)
Post-pregnancy	20.9 (0–96)

<sup>†</sup>The total weekly TCS dose was calculated by addition of daily TCS use per patient based on the potency grading system (Table 1) and the mean weekly value for each group was compared. TCS, topical corticosteroid

calculated for each patient and shown in Table 2. Good compliance was strongly associated with good control.

Twenty-seven (82%) had spontaneous vaginal births, two had instrumental deliveries (all for standard obstetric indications), and four had caesarean sections. Only one caesarean was performed because of severe VLS with scarring in a non-compliant patient. One perineal scar was complicated by the development of lichen sclerosus in this area. Perineal and abdominal scar healing was normal in all other women. Mean compliance rates increased in pregnancy from 69% of pre-pregnancy patients demonstrating good compliance to 76% during pregnancy but declined in the post-partum period to 60% of patients with adequate compliance, leading to reduced control rates in these patients.

## DISCUSSION

VLS is a chronic inflammatory skin condition affecting the anogenital area in women.<sup>1</sup> Any age group may be affected, including women of childbearing age, although it is more commonly diagnosed in older peri- or post-menopausal women.<sup>2,3</sup> Vulval disease has a significant impact on quality of life including a detrimental effect on sexual function arising from dyspareunia and apareunia.<sup>9</sup> Reported risk factors for VLS in the reproductive age group include oral contraceptive (OCP) use, particularly those with anti-androgenic properties due to the probable disturbance of androgen-dependent differentiation of the vulval skin by OCPs,<sup>3</sup> intake of carotenoids and the risk is also greater in parous women than nulliparous women, although with little tendency to increase with increasing parity.<sup>10</sup> The treatment of choice for VLS is potent to very potent topical corticosteroids.<sup>6</sup> Because of the risks of untreated VLS, which include malignancy and scarring, it is important to maintain control of the disease at all times, including pregnancy.<sup>6</sup> The incidence of LS in pregnancy is unknown.<sup>9</sup>

Our case note review of 33 pregnancies in 29 women with VLS suggests that the majority of women with VLS can deliver normally. Twenty-seven (82%) had spontaneous vaginal births, two had instrumental deliveries (all for standard obstetric indications) and four had caesarean sections. Only one caesarean was performed for VLS because of severe disease in a non-compliant

patient. One perineal scar was complicated by the development of LS in this area. This suggests that the majority of women with VLS can deliver by normal vaginal delivery. While there is limited data in this topic area, the results of previous literature appear consistent with this patient cohort. Dalziel *et al.* analysed questionnaires from 45 women with VLS and found that a total of 13 deliveries were reported, of which ten were vaginal deliveries with episiotomy, two were vaginal deliveries with episiotomy and forceps, and one was a caesarean section. In the retrospective questionnaire, two of the women stated that VLS had affected their deliveries and the one patient who had a caesarean section stated that this mode of delivery was necessary due to VLS.<sup>9</sup> Similarly, one previous case report by Haefner *et al.* documented two female subjects with newly diagnosed VLS in pregnancy who both delivered via normal spontaneous vaginal delivery.<sup>7</sup>

In this cohort, TCS requirements in pregnancy did not change significantly between the different stages of pregnancy. Using the TCS grading scale in Table 1 based on relative potencies between different TCS, the total weekly dose of recommended TCS between the subjects during their pre-pregnancy, pregnancy and post-partum stages, there was minimal difference between the mean TCS requirement (Table 2). Previous research has yielded conflicting data, with an article by Helm *et al.* showing that the effect of pregnancy was variable with half of the patients experiencing an exacerbation of LS symptoms and the other half experiencing improvement.<sup>11</sup> In contrast, other research has shown that patients experience a remission of LS in pregnancy,<sup>3</sup> however, in our cohort mean TCS requirements did not change, suggesting a similar amount of topical therapy was required to maintain symptom control. This suggests that VLS neither improved nor deteriorated in pregnancy.

Our case series showed that compliance is crucial to good outcomes, as shown in the results where those subjects with good compliance had good control and a relatively lower incidence of symptoms. This is similar to previous recommendations documented in the literature showing that maintenance treatment with TCS appears to prevent severe relapses in genital LS.<sup>6</sup>

It was noted in our subjects that there was a decline in compliance post-partum that resulted in reduced control rates and hence careful surveillance for ongoing maintenance of VLS is required. This probably relates to physical and emotional distractions in this period that detract from compliance.

If the risks and benefits of treatment with potent to super-potent topical corticosteroids in pregnancy are considered, we consider that the benefit outweighs the risk. TCS are considered safe in pregnancy and given the small surface area to which they are applied in treating VLS there is minimal potential for systemic absorption, even with more potent TCS.<sup>7</sup> Other factors increasing the systemic absorption of TCS such as use over larger surface areas, and the addition of occlusive dressings are not relevant to genital skin.<sup>6</sup> We have previously shown that prolonged use of TCS to treat genital LS is very safe, even with very potent preparations.<sup>8</sup> While general glucocorticoid toxicity, such as cataract formation and immunosuppression, have infrequently been

described in babies born to women on systemic glucocorticoid therapy, these adverse effects have not been reported with TCS.<sup>7</sup>

Limitations of this case series include the data collection from a single centre, retrospective nature of the study and small sample size. However, as the literature surrounding the management of LS in pregnancy is very limited, we feel that it is important that the medical literature contains guidance for clinicians encountering genital LS in the pregnant and potentially pregnant population.

## CONCLUSION

The data from this case note review suggest that the majority of women with VLS can give birth by normal vaginal delivery. In this cohort, TCS requirements in pregnancy did not change. TCS should be continued during pregnancy in patients with VLS at the same potency required in the non-pregnant state. Compliance is crucial to good outcomes; however, reduced compliance post-partum was identified and requires careful surveillance for ongoing maintenance of LS.

## ACKNOWLEDGEMENTS

All of the clinical images used in this manuscript were provided with patient consent.

## REFERENCES

1. Higgins CA, Cruickshank ME. A population-based case-control study of aetiological factors associated with vulval lichen sclerosus. *J Obstet Gynaecol* 2012; **32**: 271–275.
2. Smith YR, Haefner HK. Vulvar lichen sclerosus: pathophysiology and treatment. *Am J Clin Dermatol* 2004; **5**: 105–125.
3. Gunthert AR, Faber M, Knappe G *et al*. Early onset vulvar Lichen Sclerosus in premenopausal women and oral contraceptives. *Eur J Obstet Gynecol Reprod Biol* 2008; **137**: 56–60.
4. Brenner S, Politi Y. Dermatologic diseases and problems of women throughout the life cycle. *Int J Dermatol* 1995; **34**: 369–379.
5. Welsh B, Howard A, Cook K. Vulval itch. *Aust Fam Physician* 2004; **33**: 505–10.
6. Kirtschig G, Cooper S, Aberer W *et al*. Evidence-based (S3) Guideline on (anogenital) Lichen sclerosus. *J Eur Acad Dermatol Venereol* 2017; **31**: e81–e83.
7. Haefner HK, Pearlman MD, Barclay ML, Selvaggi SM. Lichen sclerosus in pregnancy: presentation of two cases. *J Low Genit Tract Dis* 1999; **3**: 260–263.
8. Lee A, Bradford J, Fischer G. Long-term management of adult vulvar lichen sclerosus: a prospective cohort study of 507 women. *JAMA Dermatol* 2015; **151**: 1061–1067.
9. Dalziel KL. Effect of lichen sclerosus on sexual function and parturition. *J Reprod Med* 1995; **40**: 351–354.
10. Sideri M, Parazzini F, Rognoni MT *et al*. Risk factors for vulvar lichen sclerosus. *Am J Obstet Gynecol* 1989; **161**(1): 38–42.
11. Helm KF, Gibson LE, Muller SA. Lichen sclerosus et atrophicus in children and young adults. *Pediatr Dermatol* 1991; **8**: 97–101.